

Successful Pregnancy Outcome in Bicornuate Uterus with Multifactorial Infertility through Ayurveda: A Case Report

Anjali Verma*

Assistant Professor, Department of Prasuti Tantra and Street Roga, Rishikul Govt. PG Ayurveda Medical College and Hospital, UAU, Haridwar, Uttarakhand, India

ABSTRACT:

Bicornuate uterus is a congenital uterine anomaly associated with infertility and recurrent pregnancy loss. Outcomes are further compromised when multiple endocrine, infectious, and systemic factors coexist. Evidence on comprehensive Ayurvedic management in such high-risk cases is limited. A 28-year-old woman presented with infertility and recurrent pregnancy loss, with a history of three first-trimester abortions. She was diagnosed with a congenital bicornuate uterus, polycystic ovarian syndrome, recurrent vulvovaginitis, and past systemic illness. Although conception had occurred earlier, pregnancy could not be sustained beyond early gestation, indicating impaired uterine receptivity rather than failure of conception. The patient underwent structured preconceptional Ayurvedic management aimed at correcting modifiable local and systemic factors and improving uterine function. Following preconceptional optimization, conception was achieved and sustained beyond the critical early gestational period for the first time. After conception, trimester-specific antenatal care was provided through *Garbhini Paricharya*. This included preventive measures to maintain maternal-fetal health and therapeutic interventions to manage pregnancy-related complaints as they arose. Symptoms were controlled conservatively across all trimesters without interruption of pregnancy. Despite the presence of a bicornuate uterus and previous recurrent pregnancy loss, pregnancy progressed to term. The patient delivered a healthy neonate by lower segment cesarean section, with no maternal or neonatal complications. This case demonstrates that integration of preconceptional Ayurvedic optimization with structured antenatal care can result in successful pregnancy outcome in multifactorial infertility and recurrent pregnancy loss associated with congenital uterine anomaly. *Garbhini Paricharya* functioned as both a preventive and disease-modifying approach. Further studies are required to assess reproducibility of this approach.

Keywords: Ayurveda, Bicornuate uterus, Female Infertility, *Garbhini Paricharya*, Preconceptional care, Recurrent pregnancy loss.

Received: 11.02.2026

Accepted: 18.03.2026

Published: 05.04.2026



This work is licensed under a [Creative Commons Attribution 4.0 International License](https://creativecommons.org/licenses/by/4.0/)
© 2026 International Journal of AYUSH Case Reports | Published by Tanaya Publication, Jamnagar.



*Corresponding Author:

Dr. Anjali Verma

Assistant Professor, Department of Prasuti Tantra and Street Roga, Rishikul Govt. PG Ayurveda Medical College and Hospital, UAU, Haridwar, Uttarakhand, India

Email: drvermaanjali@gmail.com

INTRODUCTION:

Infertility and recurrent pregnancy loss represent complex reproductive challenges, often involving multiple interacting anatomical, endocrine, immunological, and systemic factors. Congenital uterine anomalies, though relatively uncommon, are clinically significant due to their association with adverse reproductive outcomes. Among these, a bicornuate uterus, resulting from incomplete fusion of the Mullerian ducts during embryogenesis, is characterized by a dual uterine cavity and is estimated to occur in approximately 0.4 percent of individuals assigned female at birth [1]. This anomaly is a well-recognized cause of spontaneous abortion, preterm birth, and fetal malpresentation, with reported rates of recurrent pregnancy loss ranging from 15 percent to 27 percent [2].

The present case was particularly challenging due to the coexistence of a congenital uterine anomaly with multiple additional contributory factors, including polycystic ovary syndrome, recurrent vulvovaginitis, and a history of systemic illnesses such as tuberculosis and bronchial asthma. The patient also had a B-negative blood group, further complicating the reproductive milieu. Although conception could be achieved, pregnancy could not be sustained beyond early gestation, indicating that implantation failure and early gestational instability, rather than failure of fertilization alone, were central to the pathophysiology. The presence of a bicornuate uterus

significantly increases the risk of recurrent pregnancy loss, preterm birth, and malpresentation, which likely contributed to the unfavorable reproductive outcomes observed in this case [3].

In Ayurveda, infertility is described as Bandhyatva, while congenital structural abnormalities of the uterus are classified under Garbhashaya Vikriti. Congenital uterine anomalies are understood to arise from defects in Beeja, Beeja Bhaga, or Beeja Bhaga Avayava occurring during Garbhhotpatti Kala, corresponding to embryogenesis. Such disturbances impair normal organogenesis of the female reproductive system and lead to abnormal uterine formation [4,5]. Proper development of reproductive organs depends upon the integrity of Beeja and the balanced state of Doshas, and any disturbance during this critical phase may manifest clinically as infertility and recurrent pregnancy loss.

In the present case, infertility reflected impairment of all four essential factors required for conception, namely Beeja, Kshetra, Ambu, and Ritu [6]. Kshetra Dushti was evident in the form of a congenital bicornuate uterus and acquired pathology due to recurrent vulvovaginitis. Beeja Dushti manifested as ovulatory dysfunction associated with polycystic ovary syndrome. Ritu Dushti was reflected by menstrual irregularity, while Ambu Dushti was influenced by systemic illnesses such as tuberculosis and bronchial asthma, along with the B-negative blood group. As Artava, an Upadhatu of Rasa Dhatu, is directly dependent upon systemic nourishment

and metabolic status, derangement of Rasa leads to compromised Artava formation and impaired endometrial receptivity [7,8]. These factors collectively explain the complex etiopathogenesis of infertility and recurrent pregnancy loss in this patient.

This case documents the successful Ayurvedic management of multifactorial infertility and recurrent pregnancy loss associated with a bicornuate uterus through a structured continuum of care encompassing both preconceptional and antenatal management. The report is noteworthy as it highlights the expanded therapeutic role of Garbhini Paricharya, not only as a means of fetal nourishment but also as an active strategy for Swasthya Rakshana and Vikara Prashamana. Individualized application of Yuktivyapashraya Chikitsa and Sattvavajaya in the form of medications, dietary regulation, lifestyle modification, and continuous psychological counseling enabled sustained pregnancy and culminated in the delivery of a healthy neonate, despite poor prognostic factors and limited success of assisted reproductive technologies in such congenital uterine anomalies.

CASE REPORT:

A 28-year-old married female, housewife, with a married life of 1 year, presented to the OPD of *Prasuti Tantra Evum Stree Roga*, Rishikul Campus, Haridwar with the chief complaint of inability to conceive. She had a history of one spontaneous abortion at 1.5 months of gestation. The patient had been

advised surgical correction for a congenital uterine anomaly, with uncertain prognosis, leading to significant mental stress and anxiety.

Presenting Complaints

The patient presented with a chief complaint of inability to conceive, along with a history of repeated pregnancy loss. In addition to these primary concerns, she has been experiencing itching in the vulval region and burning sensation during micturition for the past 10–15 days. She also reports constipation and a reduced appetite.

Patient Consent

Written informed consent was obtained from the patient for publication of this case report and accompanying clinical details. The patient was informed about the purpose of publication, and confidentiality was maintained by anonymization of personal identifiers. The patient understood that no identifiable information would be disclosed.

Medical History

The patient has a history of menstrual irregularity for the past 3–4 years. She is a known case of tubercular spondylitis (TB spine) and has completed a full course of anti-tubercular treatment. She also has a history of bronchial asthma since childhood and reports photosensitivity in the form of allergy to sunlight.

Modern Diagnosis:

Infertility associated with Bicornuate Uterus, Polycystic Ovarian Syndrome (PCOS), Abnormal Vaginal Discharge (AVD), along with associated systemic illness (confirmed by USG)

Ayurvedic Diagnosis:

Garbhashaya Vikṛti-janya Bandhyatva associated with Bija Duṣṭi and Sarvadehika Vikāra

Clinical timeline:

The patient was first registered in June 2022. Over a period of approximately 2.5 years, the treatment protocol underwent multiple stage modifications, progressing from management of infertility to a successful full-term pregnancy. After obtaining informed consent, care was structured into two phases: Preconceptional Care, focusing on correction of infertility and systemic imbalance, followed by Antenatal Care,

aimed at Garbha-sthapana and Garbha-poshan, resulting in a healthy term outcome.

Posology Details:

The posological details of the clinical course from infertility management to the entire antenatal period are presented in three tables. Table 7 summarizes the preconceptional management covering approximately 30 clinical visits from June 2022 to February 2024. The antenatal care (ANC) period is further described in two sections based on the principles of Garbhini Paricharya. Table 8 outlines the trimester-wise dietary regimen implemented as a preventive strategy (Swasthya Rakshana), while Table 9 presents the therapeutic management of pregnancy-related conditions (Roga Avastha management) during the antenatal period.

Table1: Patient History at Baseline

Category	Parameter	Findings
Obstetric History	Obstetric Score	P0 A1 L0
	History of Abortion	One spontaneous abortion at 1.5 months gestation (3 months prior)
Menstrual History	Menarche	12 years
	Cycle	Irregular
	LMP	30/05/2022
	Duration	3 days
	Interval	30-32 days
	Flow	Moderate (2-3 pads/day)
	Pain	Mild
Personal History	Clots	Few present
	Appetite	Reduced
	Bowel	Constipated

	Micturition	Burning sensation present
	Addictions	None

Table 2: Clinical Examination Findings of patient at Baseline:

Category	Parameter	Findings
General Examination	General Condition	Fair
	Gait	Normal
	Blood Pressure	120/80 mmHg
	Pulse Rate	74 bpm, Regular
	Height	156 cm
	Weight	65 kg
	BMI	26.7 kg/m ²
	Jugular Venous Pressure	Not raised
	Pedal Edema	Absent
Systemic Examination	Central Nervous System	NAD
	Cardiovascular System	NAD
	Respiratory System	NAD
Local Examination	Per Abdomen	Soft, Non-tender
	Per Speculum Examination	External OS non-parous; cervix hypertrophied; thick curdy white discharge present in fornices and mucoid coated cervix
	Per Vaginum Examination	Mild fornicial tenderness and vaginal discharge present
	Cervical Motion Tenderness	Absent

Table 3: Laboratory Investigations at Baseline

Parameter	Result
Blood Group	B Negative
Hemoglobin	12.6 g/dL
Total Leukocyte Count (TLC)	9.49 × 10 ³ /cumm
Differential Leukocyte Count (DLC)	
Neutrophils	64.1%
Lymphocytes	26.5%
Eosinophils	8.2%
Monocytes	0.8%

Basophils	0.4%
Random Blood Sugar (RBS)	86 mg/dL
Urine Routine & Microscopy	Within normal limits
Viral Markers (HBsAg, HCV, HIV I & II)	Non-reactive
VDRL	Non-reactive
TORCH Profile	Negative
Hormonal Profile	Thyroid profile, FSH, LH, Prolactin, AMH – Within normal limits

Table 4: Imaging Study Findings at Baseline: [Figure number 1-3]

Date	Imaging Findings	Impression
30/03/2022	Uterus anteverted measuring 6.2 × 4.8 × 3.2 cm with two endometrial cavities (10.8 mm and 8.9 mm) separated by a fundal indentation suggestive of a bicornuate configuration. Myometrium homogeneous. Right ovary 3.5 × 1.6 cm; Left ovary 3.1 × 2.9 cm.	Congenital uterine anomaly suggestive of bicornuate uterus
10/09/2022	Uterus normal in size with splaying of endometrium (5.5 mm & 3.4 mm) and intercornual distance up to 3 cm, indicating separation of uterine horns. A 12 × 9 mm hypoechoic lesion in posterior myometrium with exophytic extension suggestive of sub-serosal fibroid. Ovaries bulky with multiple peripherally placed follicles and increased stromal echogenicity. Right ovary 38 × 21 mm (~17 cc); Left ovary 30 × 19 mm (~9 cc). Minimal free fluid in POD.	Bilateral PCOS morphology with sub-septate/bicornuate uterine configuration and sub-serosal fibroid

Table 5: Clinical Timeline for Pre Conceptional Period

Month of Treatment / Visit	Complaints	Patient Status	Examination and Investigation	Treatment	Outcome
June 2022 (1st visit – 14/06/2022)	Vulvar itching with abnormal vaginal discharge, burning micturition, fever, cough and cold Appetite	M/H: normal; O/H: POA1L0 P/S & P/V: cervix hypertrophied with white	Investigations: congenital uterine anomaly	<i>Dīpana-Pācana – Yoni śodhana</i> (local application); <i>Kāśahara cikitsā</i>	Marked improvement in acute symptoms

Anjali Verma. Successful Pregnancy Outcome in Bicornuate Uterus with Multifactorial Infertility through Ayurveda

	reduced, constipation, burning micturition.	discharge.			
Aug–Oct 2022 (7 visits)	Follow-up of previous complaints; generalized weakness, generalized itching, overdue menses; bleeding per vaginum for 2 days after UPT positive	M/H: irregular menses; P/H: normal; O/H: P0A2L0	UPT positive on 03/09/2022; USG (28/09/2022): RPOC, subseptate uterus with endometrial collection (?); bilateral PCOS	<i>Garbhashaya śodhana, Rakta śodhana, Artava pravartaka cikitsā</i>	Conception achieved followed by spontaneous abortion
Nov 2022 – Jan 2023 (5 visits)	Follow-up of previous complaints; cough and cold, recurrent burning micturition, vulvar itching	M/H: irregular menses	USG-TVS: septate uterus, thickened endometrium; possibility of PCOS	<i>Garbhashaya balyakara cikitsā; Kāśa–Śvāsahara; Mutrala; Yoni śodhana</i>	Complete subsidence of acute symptoms
Aug–Oct 2023 (5 visits)	Follow-up; delayed menses, generalized weakness, breathlessness	General condition stable	P/V & P/S: normal; P/A: normal; CBC: within normal limits	<i>Uttar basti (2 sittings) with Kṣāra Bala Taila; Garbhashaya balyakara and sthāpana drugs</i>	Menstrual regulation achieved
Nov 2023 – Jan 2024 (4 visits)	Follow-up; delayed/overdue menses followed by spotting; lower abdominal pain	O/H: P0A3L0; LMP: 25/11/2023	UPT positive on 07/01/2024; USG (20/01/2024): bicornuate uterus with clear uterine cavity and	<i>Balyakara, Vātānulomaka and Bija-puṣṭikara cikitsā</i>	Menstrual regularity achieved; conception occurred followed by abortion; uterine cavity remained

			subserous fibroid		clear
Feb–Mar 2024 (4 visits)	Follow-up; delayed visit, mild lower abdominal pain, facial itching	Menstrual cycles regular; O/H: G4P0A3L0; LMP: 15/02/2024	UPT positive on 16/03/2024	<i>Rakta prasādaka, Prajā sthāpana, Garbha sthāpana and Yakṛt balyakara cikitsā</i>	Pregnancy continued beyond 1.5 months

Table 6: Clinical Timeline for Antenatal Care Period

Month of Treatment / Visit	Complaints	Patient Status	Examination and Investigation	Treatment	Outcome
0–12 weeks GA (Feb–April 2024) (4 visits)	Continued gestational amenorrhea; hyperacidity, constipation, thin white vaginal discharge, mild abdominal pain	BP: normal; PR: normal	CBC & ESR: normal; Viral markers: non-reactive; APLA: within normal limits; Dual marker: normal; NT/NB scan: normal	<i>Pitta-śamana, Yakṛt rasāyana, Garbha-sthāpana, Rasāyana, Bṛṃhaṇa, Vātānulomana cikitsā</i>	Normal NT/NB scan; single live intrauterine fetus of 10 weeks 6 days
13–28 weeks GA (May–July 2024)	Continued gestational amenorrhea; generalized weakness, mild abdominal pain, recurrent vulvar and generalized itching	BP: 120/78 mmHg; PR: 78 bpm; Weight: 72 kg; Pedal edema: absent	P/A: uterus relaxed; FH corresponding to GA; FHS: 140–150 bpm, regular; USG OBS (15/06/2024): SLIUF of 16 weeks with low-lying placenta; Level II scan (24/07/2024): SLIUF of 23+ weeks, breech; cervical length	<i>Medhya rasāyana, Garbha sthāpana, Prajā sthāpana, Yakṛt rasāyana, Yoni śodhana, Garbhashaya balyakara auśadha, Rakta & Asthi pośaka, Vātānulomana, Rakta prasādaka</i>	No congenital anomalies detected; healthy continuation of pregnancy

			5.8 cm; fetal development normal		
29–32 weeks GA (Aug–Oct 2024)	Continued gestational amenorrhea; hyperacidity, frequent micturition, disturbed sleep, breathlessness	Weight: 74 kg; BP: 118/74 mmHg; PR: 74 bpm; Pedal edema: absent	P/A: uterus relaxed; FH corresponding to 30–32 weeks GA; FHR: regular, 140–150 bpm; R/S: within normal limits	<i>Amlapittahara, Vātānulomaka, Medhya rasāyana, Yakṛt rasāyana, Rakta śodhaka, Garbha sthāpaka, Śvāsa–Kāsa hara cikitsā</i>	Acute symptoms subsided
33–36 weeks GA	Continued gestational amenorrhea; disturbed sleep, loose motions, generalized itching	BP: 120/78 mmHg; PR: 72 bpm; Weight: 74 kg; Pedal edema & pallor: absent	LFT: within normal limits; USG OBS with Doppler & BPP: SLIUF of 31 weeks ±1 day; single loop of cord around neck; FHR: 131 bpm; placenta right lateral upper segment, grade II; AFI: 15.1 cm; cervical length: 3.2 cm; Doppler: normal	<i>Vātānulomaka, Garbha puṣṭikara, Asthi & Rakta poṣaka, Dīpana–Pācana, Bala taila abhyanga (adhonābhi), Pitta recaka</i>	Generalized itching subsided
36 weeks GA till term	Continued gestational amenorrhea; mild abdominal pain, hyperacidity, disturbed sleep, backache	BP: 120/80 mmHg; PR: 72 bpm; Pallor & pedal edema: absent	P/A: uterus relaxed, term-sized; FHS: regular; USG OBS color Doppler (28/10/2024): SLIUF of 36 weeks +4 days, cephalic presentation, EFW 2894 g;	<i>Vātānulomaka cikitsā; Bala taila abhyanga</i>	LSCS performed; healthy mother and neonate

			cervix—no funneling; placenta posterior, grade II; PI 1.63, RI 0.81		
--	--	--	---	--	--

Table 7: Preconceptional Ayurvedic Management (June 2022-feb 2024)

Therapeutic Objective	Formulation / Procedure (Dose & Frequency)	Route / Adjuvant
Dīpana-Pācana	Avipattikar Churna 3 g BD; Sanshamani Vati 1 tab BD	Oral with lukewarm water
Yakṛt Support	Phalatrikadi Kwath 40 ml BD; Bhumyamalaki Churna 3 g BD; Sudarshan Ghan Vati 1 tab TDS; Arogyavardhini Vati 1 tab BD	Oral before meals
Rakta Prasādana	Mahamanjishthadi Kwath 40 ml BD; Haridra Churna 2 gm with milk HS, Dhatri Lauha 250 mg TDS; Praval Pishti 500 mg BD with Gulkand 3 g	Oral
Yoni Śodhana	Chandraprabha Vati 2 tabs BD; Yoni Prakshalana with Neem Patra Kwath (as required)	Oral + Local vaginal wash
Garbhashaya Balyakara & Bija Puṣṭikara	Shatavari Churna 2 g BD + Bala Churna 2 g BD with milk; tab Ashwagandha 1TDS, Pushpadhanva Rasa 1 tab BD; Shatapushpa Churna 6 g BD Ashokarishta 20 ml BD	Oral with milk / warm water
Artava Pravartana	Rajpravartini Vati 2 tabs BD Kumayaasav 20 ml BD	Oral
Therapeutic Procedures	Matra Basti with Bala Taila for 7 days/month × 3 months; Nasya with Jyotishmati Taila for 6 days × 2 cycles; Uttarbasti with Ksheer Bala Taila 5 ml × 2 cycles	Rectal / Nasal / Intrauterine

Table 8: Trimester-wise Garbhini Paricharya as Swasthya Rakshana (Feb 2024-oct 2024)

Trimester	Preventive Measures Implemented	Diet (Ahara)	Lifestyle Measures (Vihara)	Preventive Purpose
First Trimester (0-12 weeks)	Hydration and nutritional stabilization with Rasayana support	Draksha Panka, Coconut Water, Udumbar Jala (≈200 ml every 4 hours); cow milk preparations such as daliya with	Meditation and Pranayama	Maintain hydration, support early placentation, and stabilize pregnancy

		foxnuts, coconut, and barley; soaked Draksha and Anjeer in milk; seasonal fruits and vegetables		
Second Trimester (13–28 weeks)	Brimhana and Rasayana measures with uterine relaxation	Milk products (yogurt, cheese, ghee, butter); green leafy vegetables; seasonal vegetables; Amla in diet; soups of bottle gourd and pumpkin; continuation of fruits and nourishing foods	Garbha Samvaad, meditation, pranayama, and walking after meals	Promote fetal growth, maintain uterine relaxation, and support maternal strength
Third Trimester (29 weeks–term)	Vata-regulating and preparatory measures for parturition	Ghrita incorporated in milk, daliya, and soups; continuation of nourishing foods, fruits, vegetables, and milk preparations according to appetite	Bala Taila massage to feet, soles, calf muscles, thighs, back, and abdomen; meditation and pranayama	Vata regulation and support physiological preparation for labor

Table 9: Garbhini Paricharya as Vikāra Praśamana – Trimester-wise Therapeutic Modulation (feb 2024-Oct 2024)

Trimester	Therapeutic Objective	Formulation / Procedure (Dose & Frequency)	Route / Adjuvant
Transitional phase (Infertility → Early Pregnancy)	Pitta Śamana	Avipattikar Churna 3 g BD; Shadang Paniya Kwath 40 ml BD	Oral with lukewarm water
	Yakṛt Rasāyana	Guduchi Churna 2 g + Bhumyamalaki Churna 2 g BD	Oral
	Garbha Sthāpana & Brimhana	Shatavari, Bala, Yashtimadhu, Ashwagandha 1–2 g each with milk; Garbhapal Rasa 1 BD; Phala Ghrita 5 g BD	Oral with milk
First Trimester	Pitta regulation & metabolic balance	Avipattikar Churna 3 g BD; Shadang Paniya Kwath 40 ml BD	Oral
	Yakṛt support	Guduchi Churna 2 g + Bhumyamalaki Churna 2 g	Oral

		BD	
	Garbha Sthāpana / Brimhana	Shatavari-Bala-Yashtimadhu-Ashwagandha combination; Garbhapal Rasa 1 BD; Phala Ghrita 5 g BD	Oral with milk
Second Trimester	Medhya Rasāyana	Guduchi Satva 1 g + Yashtimadhu Churna 1 g with milk	Oral
	Garbhashaya Balyakara	Shatavari combination continued with Praval Pishti 500 mg; Phala Ghrita 5 g BD	Oral
	Rakta Prasādana	Sudarshan Ghan Vati 1 TDS; Haridra Khand 3 g BD with milk; Sanshamani Vati 1 BD; Amalaki Churna 5 g HS; Dhatri Lauha 250-500 mg BD	Oral
	Mutrala / Edema management	Punarnavashtak Kwath 40 ml BD; Gokshura Churna 3 g + Punarnava Churna 2 g BD	Oral
Third Trimester	Kāsa-Śvāsa management	Laxmivilas Rasa 1 TDS; Syrup combination of Vasa, Tulsi, Somlata, Kasni 10 ml TDS; Sitopaladi Churna 3 g BD	Oral
	Sleep disturbance	Bala Taila Abhyanga; Ashwagandha tablet 1 HS	External + Oral
	Gastrointestinal disturbances	Hingwashtak Churna 3 g BD with Takra; Kutaj Ghan Vati 2 TDS; Shadang Paniya Kwath 40 ml BD	Oral
	Itching / Pitta aggravation	Jatyadi Taila local application; Sudarshan Ghan Vati 2 BD	Local + Oral
	Garbha Puṣṭikara	Phala Ghrita 5 g BD; Shatavari combination; Garbhapal Rasa; Praval Pishti 1 g + Godanti Bhasma 500 mg + mukta pisthi 120 mg BD	Oral
	Rakta Poshaka	Dhatri Lauha 250 mg BD	Oral
	Dīpana-Pācana	Hingwashtak Churna 3 g BD, Shuthi Bilwadi Kwath 40 ml BD	Oral

Preconceptional USG Findings of Patient (Figure 1-3)

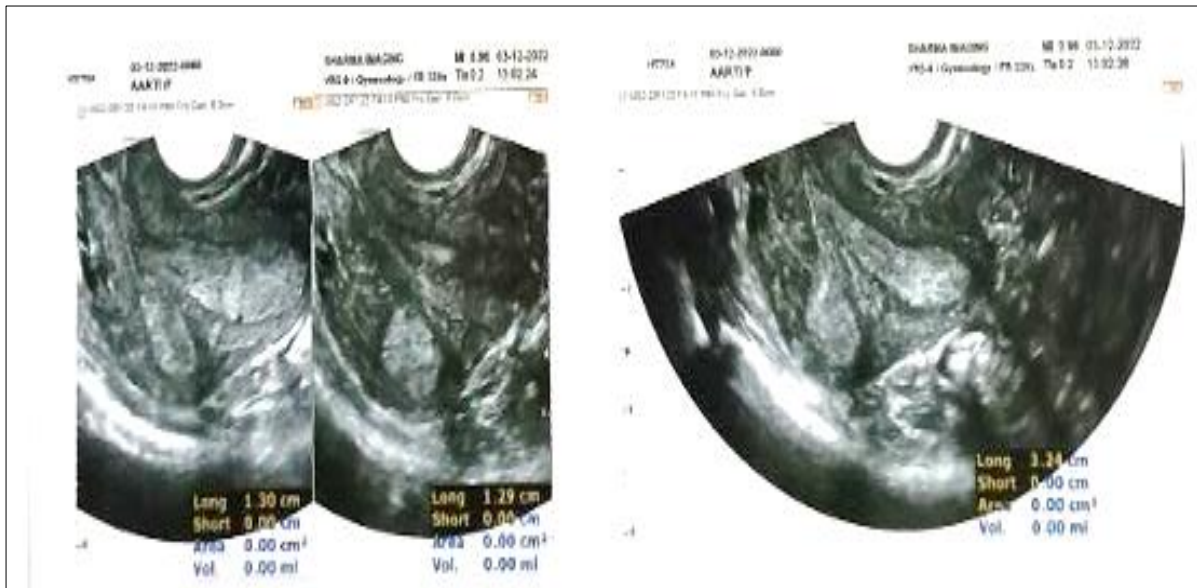

Figure-1: USG report-Bicornuate Uterus

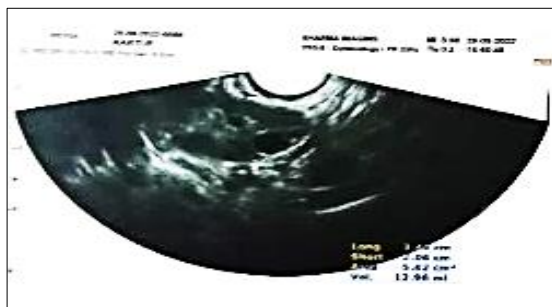

Figure 2: USG showing PCOD

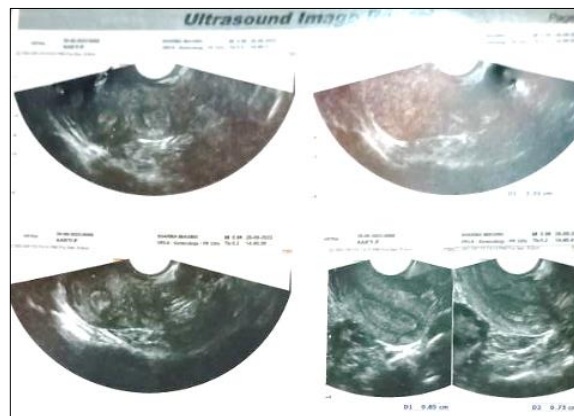


Figure-3: USG showing Serous Fibroid

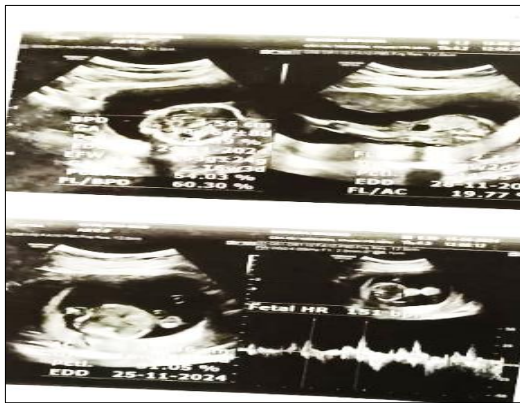

Figure 4: ANC USG-10 weeks

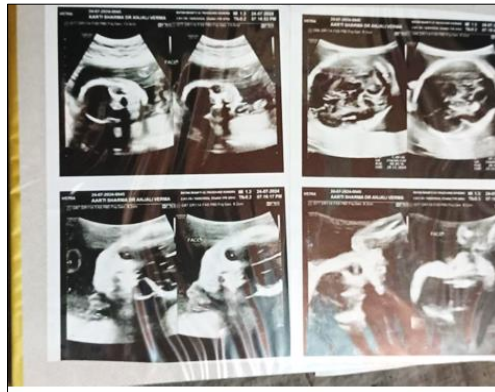

Figure-5: USG-16 weeks

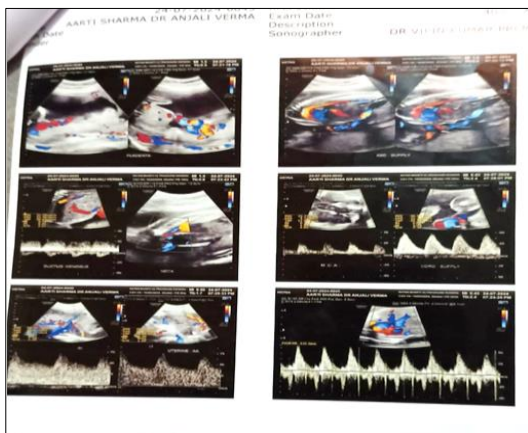


Figure-6: USG-22 weeks




Figure-7: Near Term

DISCUSSION:

1. Preconceptional Ayurvedic Management in Multifactorial Infertility and Recurrent Pregnancy Loss

The present case illustrates that infertility in the patient was not primarily due to failure of conception, but rather due to repeated early pregnancy loss occurring consistently around 1–1.5 months of gestation. This clinical pattern, evident from the timeline, indicates compromised implantation and early gestational instability rather than defective fertilization. Although a bicornuate

uterus is a recognized cause of recurrent pregnancy loss, the occurrence of repeated conceptions suggested that the congenital anomaly alone could not fully explain the unfavorable reproductive outcomes.

The preconceptional clinical timeline revealed that the initial visits were dominated by acute local and systemic complaints such as recurrent vulvovaginitis, burning micturition, cough, constipation, and reduced appetite, reflecting an unfavorable reproductive environment. Early Ayurvedic intervention focused on Dipana Pachana and Yoni shodhana

along with management of associated urinary and respiratory complaints, which resulted in marked symptomatic relief. However, despite conception occurring during these early phases of treatment, repeated abortions highlighted that symptomatic relief alone was insufficient to ensure pregnancy continuation.

Following recurrent pregnancy losses, the treatment strategy was deliberately modified toward implantation-focused management. Garbhashaya balyakara, Rakta shodhana, Yakrit rasayana, Artava pravartaka, and Bija pushtikara chikitsa were emphasized to improve uterine receptivity, systemic nourishment, and endometrial stability. Uttarbasti was incorporated as a targeted uterine intervention to strengthen the uterine milieu. Notably, sustained menstrual regularity, resolution of recurrent infections, and improved systemic stability were achieved only after prolonged uterine supportive therapy. Pregnancy was subsequently achieved and, for the first time, sustained beyond the critical early gestational period, clearly demonstrating that stepwise preconceptional optimization was essential for successful implantation in this multifactorial case. Preconceptional Ayurvedic Management summarized in table no.7

2. Transition from Infertility Management to Pregnancy Preservation: A Clinical Turning Point

Analysis of the clinical timeline identifies a distinct turning point during

February–March 2024, when pregnancy progressed beyond early gestation despite unchanged uterine anatomy. This transition marked a shift from infertility management to pregnancy preservation and coincided with stabilization of menstrual cycles, absence of active vaginal infection, improvement in systemic strength, and initiation of Garbha sthapana and Praja sthapana chikitsa.

This observation underscores that functional optimization of the uterine environment and systemic milieu played a decisive role in pregnancy continuation. The bicornuate uterus, although a persistent anatomical risk factor, did not act as an absolute barrier once uterine receptivity and systemic balance were adequately restored. This turning point reinforces the concept that in selected cases, functional correction can outweigh structural limitations in determining reproductive outcomes. Turning point detailed posology described in Table 9.

3. Garbhini Paricharya as Swasthya Rakshana: Trimester-wise Preventive Role

Once pregnancy was sustained, Garbhini Paricharya was implemented as a preventive strategy aimed at Swasthya Rakshana to minimize the risk of recurrence of pregnancy loss and anticipated obstetric complications. Given the history of recurrent pregnancy loss and the presence of a bicornuate uterus, continuous preventive care was crucial throughout gestation.

During the first trimester, a period characterized by heightened vulnerability to pregnancy loss, preventive measures focused on maintaining doshic balance, ensuring uterine stability, and supporting early placentation. Regular monitoring and supportive care resulted in normal first-trimester screening and stable fetal development.

In the second trimester, despite known risks such as low-lying placenta and breech presentation noted on ultrasonography, preventive Garbhini Paricharya helped maintain uterine relaxation and cervical stability. Subsequent scans demonstrated placental migration and normal fetal growth, suggesting effective prevention of anticipated complications. Trimester-wise dietary regulation, Rasayana, Brimhana, and Vata-regulating measures contributed to sustained maternal and fetal well-being.

During the third trimester, preventive strategies focused on mitigating Vata aggravation and supporting physiological preparation for parturition. The absence of preterm labor, hypertensive disorders, or fetal growth restriction throughout this high-risk pregnancy highlights the role of Garbhini Paricharya as a comprehensive preventive framework. The trimester-wise preventive regimen implemented as part of Garbhini Paricharya is summarized in Table 8.

4. Garbhini Paricharya as Vikara Prashamana: Trimester-wise Therapeutic Modulation

In addition to its preventive role, Garbhini Paricharya was actively employed as a therapeutic strategy for managing pregnancy-related disorders as they emerged, demonstrating its utility as Vikara Prashamana in a high-risk pregnancy.

During the first trimester, the patient experienced hyperacidity, constipation, abnormal vaginal discharge, and mild abdominal pain. These complaints were managed with Pitta shamana, Yakrit rasayana, Garbha sthapana, Brimhana, and Vatanulomana chikitsa, resulting in symptom control without interruption of pregnancy.

In the second trimester, symptoms such as generalized weakness, intermittent abdominal discomfort, and recurrent itching were addressed through Medhya rasayana, Rakta prasadhana, Garbhashaya balyakara, and supportive therapies, aligning with the developmental phase of the fetus and maternal needs. These interventions ensured maternal comfort while supporting ongoing fetal growth.

During the third trimester, rising Vata dominance manifested as breathlessness, disturbed sleep, urinary frequency, gastrointestinal disturbances, and generalized itching. These complaints were effectively managed with Vatanulomana, Garbha pushtikara, Asthi and Rakta poshaka, Dipana Pachana, and gentle external therapies such as Bala taila abhyanga. Importantly, the clinical timeline indicates that all symptoms were managed conservatively without emergency pharmacological

intervention or hospitalization, emphasizing the therapeutic adaptability of Garbhini Paricharya across gestation.

Trimester-wise Ayurvedic Interventions:

First Trimester (0–12 weeks): Garbha Sthapana and Pitta Shamana

The first trimester management focused on Garbha sthapana, prevention of early pregnancy loss, and management of Pitta-dominant complaints such as hyperacidity, constipation, and vaginal discharge. Oral formulations included Shatavari, Bala, and Ashwagandha for uterine support and maternal strength; Praval Pishti for Pitta and Rakta balance; Bhumyamalaki for Yakrit support and Rakta prasadhana; and Avipattikar Churna for management of hyperacidity and bowel regulation. Punsavana and Garbha sthapana purpose was supported through appropriate oral medications. Amalaki Churna was administered as a Rasayana and antioxidant support.

Second Trimester (13–28 weeks): Brimhana, Medhya and Rakta Prasadhana

Second trimester management emphasized Brimhana, Medhya support, and stabilization of fetal growth along with management of maternal weakness and itching. Udumbar Phala and Kharjura were used for nourishment and cooling effects, while Ghrita served as a carrier and Brimhana agent. Yashtimadhu and Guduchi were

administered for Pitta shamana, Rasayana, and immune modulation. Bhumyamalaki was continued for hepatic support. Garbhapal Rasa was given for uterine stability, while Saptamrit Lauha supported Rakta dhatu and ocular health. Amalaki was continued as Rasayana, and Sudarshan Ghan Vati was used for intermittent low-grade symptoms and metabolic regulation.

Third Trimester (29 weeks to term): Vata Anulomana and Garbha Poshana

Third trimester management focused on Vata regulation, Garbha poshana, and preparation for parturition. Avipattikar Churna was continued for bowel regulation and Pitta balance. Haridrakhand was used to manage generalized itching and allergic tendencies. Garbhapal Rasa was continued for uterine support. Praval Pishti and Mukta Pishti were administered for Pitta and Rakta balance and to manage restlessness and sleep disturbances. Lauha Rasayana supported maternal strength and Rakta dhatu. Shunthi Bilwa Kwatha was used for gastrointestinal stability. External therapy in the form of Ksheerabala Taila Abhyanga was advised to support Vata regulation and maternal comfort. Trimester-wise therapeutic modulation was implemented as part of Garbhini Paricharya to manage emerging pregnancy-related symptoms while ensuring maternal comfort and fetal stability. The detailed posological protocol is summarized in Table 9.

5. Role of Sattvavajaya and Counseling in Sustaining Pregnancy Continuity

Psychological stress is a significant yet often underrecognized contributor to infertility and pregnancy loss. In the present case, repeated abortions and advice for surgical correction with uncertain prognosis had resulted in considerable anxiety and emotional distress. The prolonged duration of treatment, extending over approximately 2.5 years, necessitated sustained psychological support to ensure treatment adherence.

Sattvavajaya chikitsa was implemented through continuous counseling, reassurance, explanation of treatment goals, and guidance regarding appropriate conduct during pregnancy. Garbha sanskara counseling was provided in accordance with gestational stage and patient-specific concerns. The consistent follow-up and compliance observed throughout the timeline reflect effective psychological support, which likely contributed to reduced anxiety, improved neuroendocrine balance, and sustained pregnancy continuation.

6. Clinical Significance and Limitations

This case demonstrates that successful pregnancy outcome can be achieved in multifactorial infertility and recurrent pregnancy loss associated with congenital uterine anomaly through a comprehensive and individualized Ayurvedic approach. The integration of preconceptional optimization, preventive and therapeutic Garbhini Paricharya, and psychological support

represents a continuum of care rather than isolated intervention. The novelty of this report lies in highlighting Garbhini Paricharya as an active disease-modifying strategy across pregnancy, rather than solely a fetal nourishing regimen. Trimester-wise USG and Doppler scans of the patient during the first, second, and third trimesters are illustrated in **Figure 4-7**.

However, as a single case report, the findings cannot be generalized. Structural correction of the bicornuate uterus was not undertaken, and outcomes may vary depending on the severity of uterine anomaly and associated systemic factors. Nevertheless, the longitudinal clinical timeline provides valuable insight into the potential role of Ayurveda in managing complex infertility and high-risk pregnancy, warranting further systematic clinical research.

CONCLUSION:

This case demonstrates that successful pregnancy in a bicornuate uterus with multifactorial infertility can be achieved through rational Ayurvedic management integrating infertility treatment with Garbhini Paricharya and Chikitsa. The clinical course highlights the importance of preconceptional optimization and structured antenatal care in improving pregnancy outcomes in such complex cases.

Conflict of interest: The author declares that there is no conflict of interest.

Guarantor: The corresponding author is the guarantor of this article and its contents.

Source of support: None

How to cite this article:

Anjali Verma. Successful Pregnancy Outcome in Bicornuate Uterus with Multifactorial Infertility through Ayurveda: A Case Report. Int. J. AYUSH Case Reports. 2026; 10(1-B): 1-19.

REFERENCES:

1. Kaur P, Carlson K, Panneerselvam D. Bicornuate uterus. In: StatPearls [Internet]. Treasure Island (FL): StatPearls Publishing; 2025 Jan-. Updated 2025 Jul 6. Available from: <https://www.ncbi.nlm.nih.gov/books/NBK560859/>
2. Choudhary S, Jelly P, Mahala P. Successful outcome of pregnancy in bicornuate uterus: a case report. Int J Reprod Contracept Obstet Gynecol. 2019;8(10):4086–4089.
3. Cunningham FG, Leveno KJ, Bloom SL, Dashe JS, Hoffman BL, Casey BM, et al. Congenital genitourinary abnormalities. In: Williams Obstetrics. 26th ed. New York: McGraw-Hill; 2018. p.103.
4. Shastri K, Chaturvedi G. Charaka Samhita. Vidhyotini Hindi commentary Reprint ed. Sharir Sthana, Chapter 3, Verse 17. Chaukhambha Bharati Academy, Varanasi. 2001. p.865.
5. Shastri K, Chaturvedi G. Charaka Samhita. Vidhyotini Hindi commentary, Reprint ed. Sharir Sthana, Chapter 4, Verse 30. Chaukhambha Bharati Academy, Varanasi. 2001. p.877.
6. Shastri AD. Sushruta Samhita. Ayurveda Tattva Sandipika Hindi commentary Reprint ed. Sharir Sthana, Chapter 2, Verse 35. Chaukhamba Sanskriti Sansthan, Varanasi. 2018. p.19.
7. Shastri AD. Sushruta Samhita. Ayurveda Tattva Sandipika Hindi commentary Reprint ed. Sutra Sthana, Chapter 14, Verse 10. Chaukhamba Sanskriti Sansthan, Varanasi. 2018. p.65.
8. Acharya YT. Sushruta Samhita with Dalhana commentary. Sutra Sthana, Chapter 14, Verse 10. Chaukhamba Surbharati Prakashan, Varanasi. 2003. p.59.